

ORIGINAL ARTICLE

Morphology of the Lingual Dorsal Surface and Oral Taste Buds in Italian Lizard (*Podarcis sicula*)F. Abbate*[†], M. C. Guerrero[†], G. Montalbano, R. Zichichi, A. Germanà and E. Ciriaco

Address of authors: Department of Morphology, Biochemistry, Physiology and Animal Production—Section of Morphology, University of Messina, Messina 98168, Italy

***Correspondence:**

e-mail: abbatfef@unime.it

[†]These authors contributed equally to this paper.

With 4 figures

Received October 2009; accepted for publication December 2009

doi: 10.1111/j.1439-0264.2010.00992.x

Summary

The Italian lizard (*Podarcis sicula*) is the most diffused reptile in Italy, but it is also present in other European countries. This lizard belongs to the Lacertidae family, lives near walls, slants and along the borders of the paths; its diet includes bugs and arachnids. No data are so far available in literature about the three-dimensional morphology of the tongue of *Podarcis sicula*, therefore the aim of the present paper was to study by scanning electron and light microscopy the three-dimensional characteristics of the dorsal lingual surface and moreover the presence of chemosensory receptors like the taste buds in the oral cavity. Our results demonstrate that the *Podarcis sicula* tongue is a triangular muscular membranous organ, dorsoventrally flattened and that three different areas can be observed: a bifid apex, a body and a root. No papillae were observed in the apex, characterized by a flattened mucosa and by two deep median pouches. In the body cylindrical papillae with a flat surface are present, aborally gradually substituted by imbricated papillae. Foliate-like papillae were observed in the lateral parts of the tongue body. No sensory structures were showed on the lingual dorsal surface, while they were numerous in the oral cavity, particularly on the gingival epithelium. The light microscopy shows, on the dorsal surface, a stratified pavementous not keratinized epithelium, conversely keratinized along the ventral surface. Many caliciform cells on the lateral parts of the papillae, deputed to the secretion of mucus, were also observed. Therefore, the results obtained in this paper could give a contribution to the knowledge of the tongue anatomy in a species widely diffused in different European countries and could be of help for clinical purposes in reptiles.

Introduction

The Italian lizard or rural lizard (*Podarcis sicula*), in past considered a typical species of Sicily, is the most diffused reptile in Italy but is also present in France, Switzerland, Slovenia, etc. (Isailovic et al., 2005). This saurian, belonging to the Lacertidae Family, is easily observable in the anthropized zones in proximity of walls, sunny rocky slants and along the borders of the paths, never away from a possible shelter. The diet essentially includes bugs and arachnids. Recent data related to the morphology of the oral cavity of numerous species belonging to the Family of Lacertidae, suggest a notable species-specific and

inter-specific variety (Herrel et al., 2005). The epithelium of the lingual surface, in the various reptiles, observed by light microscopy (Smith, 1986; Schwenk, 1988; Delheusy et al., 1994) and electron microscopy (Iwasaki and Miyata, 1985; Rabinowitz and Tandler, 1986; Iwasaki, 1990) shows notable differences. Just for this extreme variability the lizards represent above all a particularly interesting group for the morpho-functional study of the tongue (Schwenk, 1988; Schwenk and Bell, 1988; Schwenk and Throckmorton, 1989; Cooper, 1997). This last, considered a key element in the evolution from the aquatic life to that terrestrial, is specialized more and more in the transport of alimentary products inside the oral cavity in a

low density medium like the air (Iwasaki and Miyata, 1985; Iwasaki, 1990). The tongue has different functions in the different steps; from the capture of the prey to the transport of the same one inside the oral cavity and the following swallowing (Iguania) (Bell, 1989, 1990; Abbate et al., 2008) to the chemoreceptive function (Scleroglossa) (Cooper, 1995; Schwenk, 2000). The tongue is, also, a useful organ to drink and to breathe and in the defensive behaviours (Bels et al., 1994). Close correlations intervene between the morphology of an organ and the function that it develops (McClung and Goldberg, 2000; Schwenk, 2000). In literature, numerous data are present regarding the structure and the function of the tongue of Iguanidae (Abbate et al., 2008) and Varanidae (Smith, 1984, 1986; Herrel et al., 1998); the bibliographical data related to the morphology of the tongue of the intermediary order of the Scincomorpha, the most numerous group of Sauri, are, instead, scarce (Herrel et al., 1999; Schwenk, 2000; Abbate et al., 2009;). Since really in the Lacertidae the tongue shows both the functions of prehension and transport (Goosse and Bels, 1992a; Urbani and Bels, 1995) and chemoreceptorial one (Goosse and Bels, 1992b), we decided to give a contribution to the knowledge of the morpho-functional aspects of the tongue of *Podarcis sicula*. The aim of this study was mainly focused to study by scanning electron microscopy and light microscopy the three-dimensional structure of the dorsal surface of the tongue and the oral cavity chemosensory structures.

Material and Methods

Ten subjects of *Podarcis sicula* from lizard farms were used for this study. After the withdrawal of the heads, for a good exposure of the tongue, the temporo-mandibular joints were disarticulated and cut. The samples were fixed in 2.5% glutaraldehyde. After several rinsings in the same phosphate buffer, they were dehydrated in a graded alcohols series, critical-point dried in a Balzers CPD 030, sputter coated with 3 nm gold in a Balzers BAL-TEC SCD 050 and examined under a Cambridge Stereoscan 240 electron microscope (Zeiss ex Cambridge Instruments, Cambridge, UK) operating with an accelerating voltage of 20 kV. For ascertaining the morphological details better, some pieces were washed in 5% neutral Extran (Merck, Darmstadt, Germany) to remove the mucus. For light microscopy, the routine methods for haematoxylin and eosin staining were carried out.

Results

The *Podarcis sicula* tongue is an elongated muscular membranous organ, with a triangular shape, dorsoventrally flattened. Three different areas can be observed: an

apex, a body and a root (Fig. 1). Along the dorsal surface of the tongue, numerous papillae with different form and distribution are evident. The apex is bifid, without papillae and characterized, on each part, by two deep median pouches (Fig. 2a). The change from the apex to the body of the tongue is marked by a clear demarcation line (Fig. 2b).

The mucosa, flattened at the apex level, arises in plicae, forming cylindrical papillae with a flat surface in the anterior part of the body (Fig. 2d), that gradually are substituted, in the posterior part, by imbricated papillae with an irregular free edge (Fig. 2e). Along the lateral edges of the tongue body foliate-like papillae are evident, becoming greater aborally, converging medially, at root level (Fig. 2c,f).

On all the dorsal surface of the tongue, sensory structures could not be observed, but, conversely numerous taste buds were present in the oral cavity, particularly on the gingival epithelium (Fig. 3a–d).

The light microscopy shows on the lingual dorsal surface a stratified pavementous not keratinized epithelium, conversely keratinized along the ventral surface (Fig. 4a). The flattened mucosa of the apex changes in the body for the presence of parallel papillae with an aboral orientation and evident inter-papillary spaces with the presence of melanin in the papillae and in the layers below (Fig. 4b). On the tongue root, high foliate-like papillae, aborally oriented, with many caliciform cells on the lateral parts, deputed to the secretion of mucus, useful during the food swallowing, were observed (Fig. 4c).

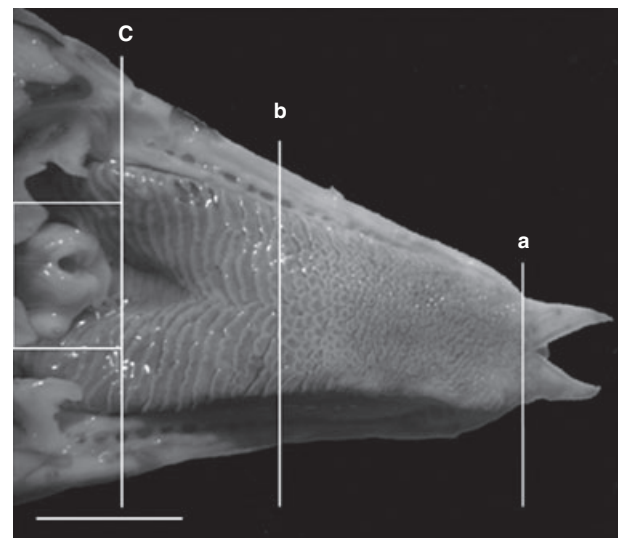


Fig. 1. Stereomicrograph of the tongue dorsal surface: The lines divide the three different areas: a: the limit of the bifid apex; from a to b: the body of the tongue; from b to c: the root. The rectangle, on the left encloses the epiglottis, scale bar: 5 mm.

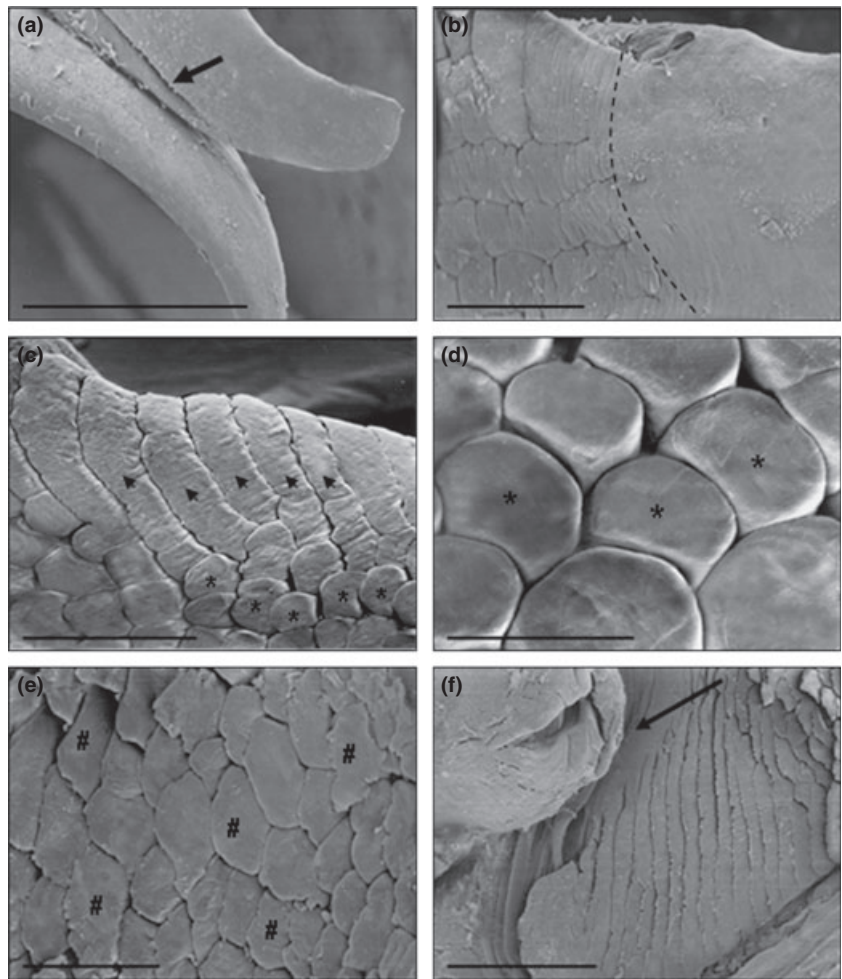


Fig. 2. (a) Scanning electron micrograph of the bifid apex of the tongue. The arrow indicates the deep median pouches, scale bar: 500 μm ; (b) the passage between the mucosa of the apex and the body is marked by a broken line, scale bar: 200 μm ; (c) lateral part of the body with large foliate-like papillae, scale bar: 100 μm ; (d) in the anterior part of the body cylindrical papillae with flat surfaces (asterisks), scale bar: 200 μm ; (e) the posterior part with imbricated papillae (wickets) with an irregular free edge, scale bar: 200 μm ; (f) the root of the tongue characterized by great foliate-like papillae, the arrow indicates the epiglottis; scale bar: 1 mm.

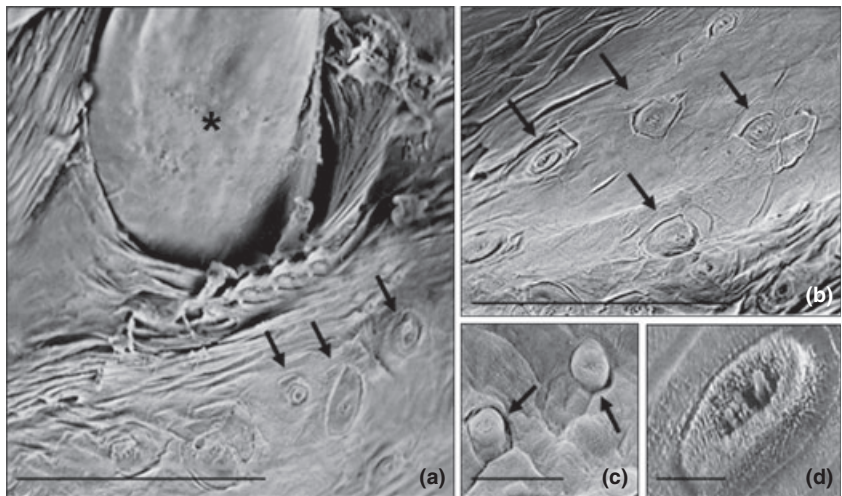


Fig. 3. (a) Scanning electron micrograph of the gingival epithelium of the oral cavity. The asterisk indicates a tooth while the arrows indicates the taste buds, scale bar: 100 μm . (b, c) The taste buds at higher magnification indicated by arrows, scale bar: b: 100 μm ; c: 200 μm . (d) A taste bud with taste hair and the taste pore, scale bar: 5 μm .

Discussion

The morphological characteristics of the tongue in vertebrates are strictly related to the functions used in the

mechanics of food taking, considering, also, that the tongue is very important as a key in the evolution of a terrestrial lifestyle (Herrel et al., 2005). The observations carried out by scanning electron and light microscopy

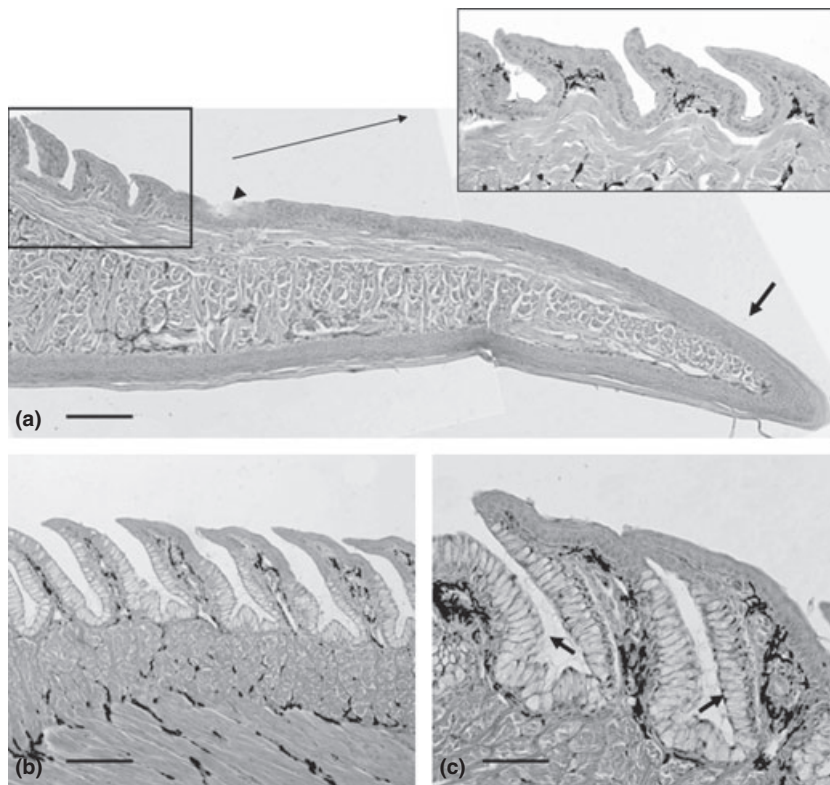


Fig. 4. (a) Light micrograph (haematoxylin and eosin staining) of a transverse section of the stratified pavementous not keratinized epithelium of the apex without papillae (arrow), while the ventral surface is keratinized. The body is characterized by parallel cylindrical papillae with an aboral orientation and evident inter-papillary spaces, better showed in the insert; the arrowhead indicates the limit between the apex and the body, scale bar: 100 μm ; (b) at higher magnification the cylindrical papillae with flattened surfaces and the presence of melanin in the papillae and in the layers below; scale bar: 100 μm ; (c) the tongue root with foliate-like papillae, with many caliciform cells on the lateral parts indicated by arrows; scale bar: 30 μm .

demonstrated the presence of three different areas that we indicated as apex, body and root. The different morphological aspects of the dorsal surface in the three areas let hypothesize different roles during the sequence of events involved in the food taking: the apex could have a role not only in food prehension and in prey transport inside the oral cavity, but also in the chemosensory perception because of the presence of two deep median pouches, that hypothetically could carry air to the vomero-nasal organ to be analysed to reveal the presence of prey, predators or partners. This hypothesis should be confirmed in further studies. The tongue body could be essential in the prey keeping inside the oral cavity preventing the escape not only for the aboral orientation of the papillae but also for the presence of deep inter-papillary spaces determinant for the adhesion, while the root could have an important role helping the deglutition for the presence of numerous caliciform cells. The morphological description matches that of other reptiles with terrestrial lifestyle and can be correlated, without any doubt, with the diet and also the different roles described are in accordance with the behaviour and ecological information about these species (Smith, 1986, 1988; Bell, 1989, 1990; Delheusy et al., 1994; Cooper, 1997; Bonacci et al., 2008; Abbate et al., 2009).

The taste buds present in the oral cavity, especially on the gingival epithelium and reported in literature as complex pear or onion-shaped sensory organs containing dif-

ferent types of sensory cells reveal their role as mechanoreceptive or as paracrine or as neuroendocrine cells (Witt and Reutter, 1988; Germanà et al., 2004; Roper, 2006) while their absence on the lingual surface confirms the mechanical functions of the papillae and their important role in the swallowing phase.

For the absence of previous data about the three-dimensional morphology of the dorsal lingual surface of this reptile and for the results obtained the data described in this paper could give a contribution to the knowledge of the tongue anatomy in a species widely diffused in different European countries and could be of help for clinical purposes in reptiles.

Acknowledgements

The authors thank Mr V. Sidoti for his technical assistance particularly working on the electron micrographs. This study was supported by a grant from the University of Messina (PRA 2005).

References

- Abbate, F., G. Latella, G. Montalbano, M. C. Guerrero, M. B. Levanti, and E. Ciriaco, 2008: Scanning electron microscopical study of the lingual epithelium of green iguana (*Iguana iguana*). *Anat. Histol. Embryol.* **37**, 314–316.

- Abbate, F., G. Latella, G. Montalbano, M. C. Guerrero, G. P. Germanà, and M. B. Levanti, 2009: The lingual dorsal surface of the blue-tongue skink (*Tiliqua scincoides*). *Anat. Histol. Embryol.* **38**, 348–350.
- Bell, D. A., 1989: Functional anatomy of the chameleon tongue. *Zool. J. Anat.* **119**, 313–336.
- Bell, D. A., 1990: Kinematics of prey capture in the chameleon. *Zool. J. Anat.* **94**, 247–260.
- Bels, V. L., M. Chardon, and K. V. Kardong, 1994: Biomechanics of the hyolingual system in squamata. In: *Biomechanics of Feeding in Vertebrates* (V. L. Bels, M. Chardon and P. Vandewalle, eds). Berlin: Springer-Verlag. pp. 197–240.
- Bonacci, T., G. Aloise, P. Brandmayr, T. Z. Brandmayr, and M. Capula, 2008: Testing the predatory behaviour of *Podarcis sicula* (Reptilia: Lacertidae) towards aposematic and non-aposematic preys. *Amphibia-Reptilia* **29**, 449–453.
- Cooper, W. E., 1995: Foraging mode, prey chemical discrimination, and phylogeny in lizards. *Anim. Behav.* **50**, 973–985.
- Cooper, W. E., 1997: Correlated evolution of prey chemical discrimination with foraging, lingual morphology and vomeronasal chemoreceptor abundance in lizards. *Behav. Ecol. Sociobiol.* **41**, 257–265.
- Delheusy, V., G. Tobeau, and V. L. Bels, 1994: Tongue structure and function in *Oplurus cuvieri* (Reptilia: Iguanidae). *Anat. Rec.* **238**, 263–276.
- Germanà, A., T. González-Martínez, S. Catania, R. Laurà, J. Cobo, E. Ciriaco, and J. A. Vega, 2004: Neurotrophin receptors in taste buds of adult zebrafish (*Danio rerio*). *Neurosci. Lett.* **354**, 189–192.
- Goosse, V., and V. L. Bels, 1992a: Kinematic and functional analysis of feeding behaviour in *Lacerta viridis* (Reptilia: Lacertidae). *Zool. Jb. Anat.* **122**, 187–202.
- Goosse, V., and V. L. Bels, 1992b: Kinematic analysis of tongue movements during chemosensory behaviour in the European green lizard, *Lacerta viridis* (Reptilia: Lacertidae). *Can. J. Zool.* **70**, 1886–1896.
- Herrel, A., J. P. Timmermans, and F. De Vree, 1998: Tongue flicking in agamid lizards: morphology, kinematics and muscle activity patterns. *Anat. Rec.* **252**, 102–116.
- Herrel, A., F. De Vree, V. Delheusy, and C. Gans, 1999: Cranial kinesis in gekkonid lizards. *J. Exp. Biol.* **202**, 3687–3698.
- Herrel, A., N. Canbek, U. Ozelmas, M. Uyanoglu, and M. Karakaia, 2005: Comparative functional analysis of the hyolingual anatomy in lacertid lizards. *Anat. Rec. A. Discov. Mol. Cell. Evol. Biol.* **284**, 561–573.
- Isailovic, J. C., M. Vogrin, C. Corti, V. P. Mellado, P. Sá-Sousa, M. Cheylan, and J. Pleguezuelos, 2005: *Podarcis sicula*. In: 2008 IUCN Red List of Threatened Species. Available at: <http://www.iucnredlist.org>.
- Iwasaki, S., 1990: Fine structure of the lingual epithelium of the lizard *Gekko japonicus* (Lacertilia, Gekkonidae). *Am. J. Anat.* **187**, 12–20.
- Iwasaki, S., and K. Miyata, 1985: Scanning electron microscopy of the lingual dorsal surface of the Japanese lizard, *Takydromus tachydromoides*. *Okajimas Folia Anat. Jpn.* **62**, 15–26.
- McClung, J. R., and S. J. Goldberg, 2000: Functional anatomy of the hypoglossal innervated muscles of the rat tongue: a model for elongation and protrusion of the mammalian tongue. *Anat. Rec.* **260**, 378–386.
- Rabinowitz, T., and B. Tandler, 1986: Papillary morphology of the tongue of the American chameleon: *Anolis carolinensis*. *Anat. Rec.* **216**, 483–489.
- Roper, S. D., 2006: Cell communication in taste buds. *Cell. Mol. Life Sci.* **63**, 1494–1500.
- Schwenk, K., 1988: Comparative morphology of the lepidosaur tongue and its relevance to squamate phylogeny. In: *Phylogenetic Relationships of the Lizard Families* (R. Estes and G. Pregill, eds). Stanford: Stanford University Press. pp. 569–598.
- Schwenk, K., 2000: Feeding in Lepidosaurs. *Feeding: Form, Function and Evolution in Tetrapod Vertebrates*. San Diego, CA: Academic Press. pp. 175–291.
- Schwenk, K., and D. A. Bell, 1988: A cryptic intermediate in the evolution of chameleon tongue projection. *Experientia* **44**, 697–700.
- Schwenk, K., and G. Throckmorton, 1989: Functional and evolutionary morphology of lingual feeding in squamate reptiles: phylogenetics and kinematics. *J. Zool. Lond.* **219**, 153–175.
- Smith, K. K., 1984: The use of the tongue and hyoid apparatus during feeding in lizards (*Ctenosaura similis* and *Tupinambis nigropunctatus*). *J. Morph.* **202**, 115–143.
- Smith, K. K., 1986: Morphology and function of the tongue and hyoid apparatus in *Varanus* (Varanidae: Lacertilia). *J. Zool. Lond.* **187**, 261–287.
- Smith, K. K., 1988: Form and function of the tongue in agamid lizards with comments on its phylogenetic significance. *J. Morph.* **196**, 157–171.
- Urbani, J. M., and V. L. Bels, 1995: Feeding behaviour in two scleroglossan lizards: *Lacerta viridis* (Lacertidae) and *Zonosaurus laticaudatus* (Cordylidae). *J. Zool. Lond.* **236**, 265–290.
- Witt, M., and K. Reutter, 1988: Comparative lectin histochemical investigation of the taste buds of different vertebrates. *Acta Histochem. Suppl.* **36**, 405–408.